

Cystic Pancreatic Lesions

Authors

- Martin Wang
- Xue Jn Wu
- Lian Xie
- Wu CF

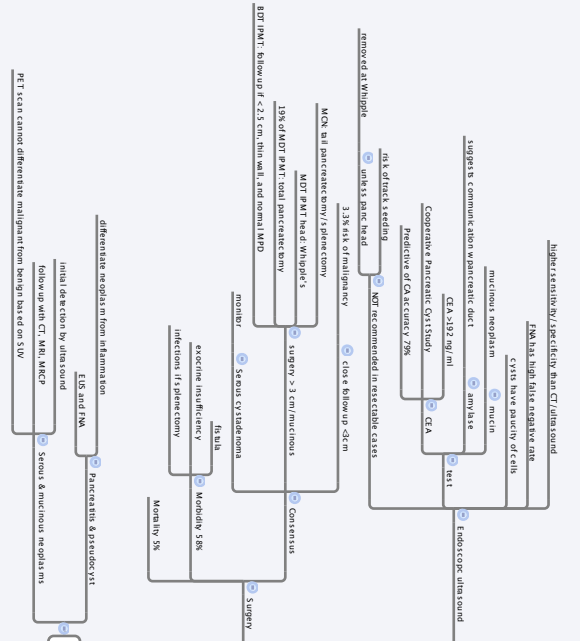
Follow-up

- PMN
- MCN
- Invasive CA
- AdenoCA & mts

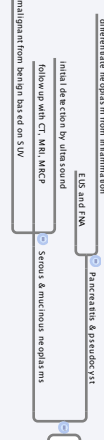
Intro

- Pseudocyst
- Stenos cystic pancreatic neoplasm
- Mucinous cystic neoplasm (MCN)
- Intraductal papillary mucinous tumor (IPMT)

Management



Imaging & Management



Classification

